

## Complete Labial Fusion in a Post Menarche Adolescent Girl

Anum Fatima Parekh, Ayesha Khan\*, Shahzad Ali

*Department of Urology, Jinnah Postgraduate Medical Centre, Karachi, Pakistan.*

**Abstract:** Labial fusion is commonly seen in pre-pubertal girls but is rarely reported in adolescent females after menarche. Its main cause is low estrogen levels. A patient can be completely asymptomatic and self-limiting or present with a wide range of symptoms which can vary from urinary tract infection, urine retention, incontinence, dyspareunia, etc. We present a case of a 12-year-old female who presented in our department with a complaint of difficulty in voiding and lower urinary tract symptoms. After a detailed examination, she was diagnosed with labial fusion for which adhesiolysis was done and patient remained asymptomatic after it.

**Keywords:** Labial fusion, Lower urinary tract symptoms, Adhesiolysis, Dyspareunia, Urine retention, Incontinence.

### INTRODUCTION

Labial fusion is the complete or partial adherence of the labia minora, also referred to as labial agglutination or labial adhesion [1]. It is rarely symptomatically present in pubertal girls due to the presence of a sufficient level of estrogen [2]. The main cause of labial fusion is because of low estrogen levels accompanied by local inflammation due to vulvovaginitis, diarrhea, nappy rash, and scratching of the vulva. It is usually asymptomatic, self-limiting, and doesn't require any treatment. Various treatment modalities are available in non-resolving symptomatic females which include both medical and surgical options. We have reported this case because of the rarity of its prevalence in pubertal girls and to discuss the importance of proper clinical examination.

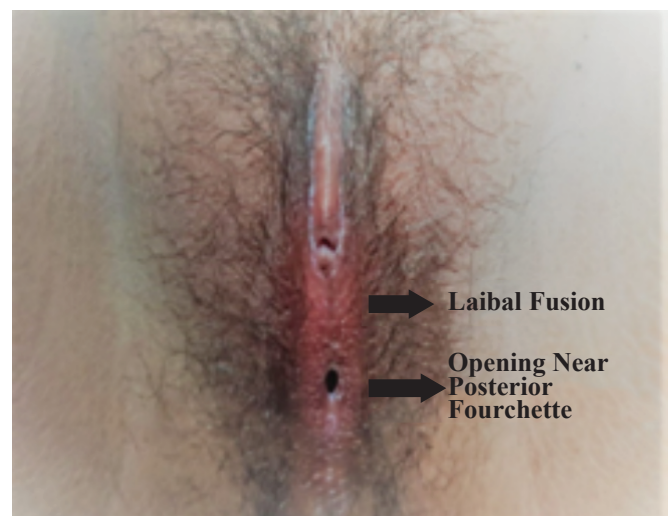
### CASE REPORT

A 12-year-old girl, who had achieved her menarche 1 year back, was brought by her mother to the outpatient department, with complaints of weak stream, dysuria, and ballooning of labia during micturition for the last four months. She had a history of vulvovaginitis nine months back after that she start experiencing these symptoms. The intensity of these symptoms increased from moderate to severe during menstruation. Her menstrual cycle was regular and the flow was normal. On clinical examination, the girl was of average height and built, and secondary sexual characteristics corresponded to her age. The abdomen was soft and non-tender with no visceromegaly appreciable. Examination of the external genitalia revealed fused labia minora in the midline, with a small opening near the posterior fourchette through which both urine and menstrual blood flowed. The urethral meatus and vaginal opening were not visualized. Diagnosis of labial fusion was made (Fig. 1).

Her baseline investigations were normal. Urine detail report showed 2 - 3 leukocytes/high-power-field. There was no growth in the urine culture. Ultrasound imaging revealed normal kidneys and bladder. A plan was made for examination under anesthesia and labial adhesiolysis.

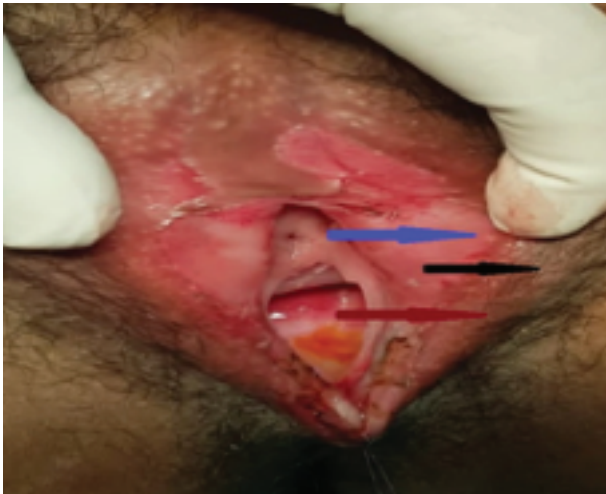Under general anesthesia, a lithotomy position was made. Adhesiolysis was done and labia separated in the midline, which revealed a normal nulliparous cervix, vagina, and normal external genitalia. Margins were everted and the interrupted suture was taken from above downwards on both sides with 3-0 vicryl. Cystoscopy showed normal urethra and bladder. Vaginoscopy was also normal (Figs. 2, 3).

The dressing was done with a lubricated gauze piece kept in between the labia. Oral antibiotics were given. She was discharged and advised to apply estrogen cream. A follow-up examination revealed a normal appearance of the vulva and no adhesions.

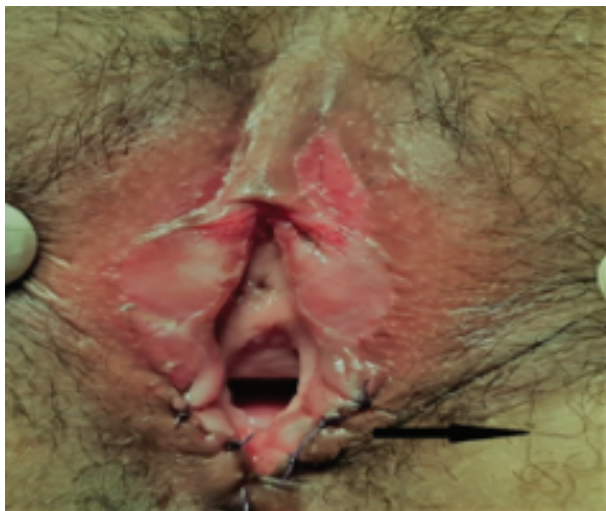

**Fig. (1).** Fused Labia Minora with a Small Opening Near Posterior Fourchette.

\*Address correspondence to this author at the Department of Urology, Jinnah Postgraduate Medical Centre, Karachi, Pakistan.  
Email: ayeshakhan.smc@gmail.com



**Fig. (2).** Blue Arrow: Urethra, Black Arrow: Labia Minora, Red Arrow: Vagina.



**Fig. (3).** Black Arrow: Margins Everted and Sutured with Vicryl 3/0.

## DISCUSSION

Labial fusion develops due to inflammation of estrogen-deficient labial skin. During the healing process, the labial fold fuses due to proximity and forms a thin membrane that hides partially or completely urethral and vaginal opening. It is very rarely present in < 3 months of an infant due to the presence of a sufficient level of estrogen from the mother. In the pubertal group, its occurrence is related to vulvar trauma or inflammation which usually results from either vulvovaginitis, nappy rash, poor hygiene, diarrhea, genital herpes, or sexual abuse. My patient had a history of one episode of vulvovaginitis before experiencing urinary complaints that could be the cause of her labial fusion.

Labial fusion in the post-menopausal group is because of the atrophic labial skin because of hypoestrogenism. The atrophic epithelium is more susceptible to irritation and rawness than estrogenized skin and has the potential to form fibrous adhesions following trauma [3, 4]. This condition is asymptomatic > 35% of patients [5]. Rarely does it present with urinary symptoms, dysmenorrhea, bladder outlet obstruction or cause upper tract dilatation [6]. This condition is commonly misdiagnosed leading to unnecessary investigations as in our case patient presented with urinary symptoms for which she was treated with antibiotics multiple times with the impression of a UTI. Labial fusion is diagnosed by a proper examination. It appears as a thin, pale, semi-translucent membrane between the labia minora or can look like an imperforate hymen or malformation of the genital tract like vaginal atresia etc. [5, 7].

In asymptomatic cases, no treatment is required. In all symptomatic patient treatment typically consist of vulvar hygiene and topical estrogen cream application once or twice daily for not more than 6 weeks [3]. A pea-sized amount of estrogen cream is applied using a cotton bud along the line of fusion. Its success rates vary between 50% - 100%, depending on the duration of treatment and density of adhesions along with other factors [5]. Use of estrogen or a bland emollient, such as petroleum jelly is recommended for maintenance of labial separation [4]. The other option is the application of local betamethasone cream. In a retrospective review of 19 girls, a course of local betamethasone cream 0.05% for 4–6 weeks was shown to be successful in 68% of cases who were initially treated with local estrogen or surgical adhesiolysis [8]. Manual separation of adhesions has also been reported to resolve pediatric labial adhesions [2]. Surgical adhesiolysis under general anesthesia may be required in about 5-10% of cases [7]. In our case, we opted for adhesiolysis due to thick adhesion, followed by cystoscopy and vaginoscopy. Postsurgical separation and local estrogen cream application were advised. In recurrent cases, amniotic membrane, and rotational skin graft after surgical incision has been described in the literature [5].

## CONCLUSION

Labial adhesion is uncommonly reported in post menarche adolescent girls. It is often misdiagnosed due to improper examination. Hence, every patient should be examined thoroughly. Symptomatic patients can be treated pharmacologically or surgically along with local hygiene.

## CONFLICT OF INTEREST

Declared none.

## ACKNOWLEDGEMENTS

Declared none.

## REFERENCES

- [1] McCann J, Wells R, Voris J. Genital findings in prepubertal girls selected for nonabuse: A descriptive study. *Pediatrics* 1990; 86(3): 428-39.
- [2] Singh V, Sinha S, Singh A. Labial agglutination in a pubertal girl. *J Clin Diagn Res* 2018; 12(1): QD01-QD02.
- [3] Michala L, Creighton SM. Fused labia: A paediatric approach. *Obstet Gynaecol* 2009; 11(4): 261-4.
- [4] Girton S, Kennedy CM. Labial adhesion: A review of etiology and management. *Top Obstet Gynecol* 2006; 26(23): 1-5.
- [5] Ethirajan S, Selvamuthu B, Jayashree K, Kumar S, Fathima N. Labial adhesion in a pubertal girl-a commonly misdiagnosed entity: A case report. *J South Asian Fed Obstet Gynaecol* 2021; 13(1): 71-3.
- [6] Norbeck JC, Ritchey MR, Bloom DA. Labial fusion causing upper urinary tract obstruction. *Urology* 1993; 42(2): 209-11.
- [7] Kumar GK. Labial adhesion: An office problem in pediatric urology. *Pediatr Urol Case Rep* 2016; 4(1): 248-52.
- [8] Myers JB, Sorensen CM, Wisner BP, Furness III PD, Passamaneck M, Koyle MA. Betamethasone cream for the treatment of pre-pubertal labial adhesions. *J Pediatr Adolesc Gynecol* 2006;19(6): 407-11.

Received: July 09, 2022

Revised: September 15, 2022

Accepted: September 19, 2022

© 2022 National Journal of Health Sciences.

This is an open-access article.